

# Medicilon Ophthalmology Platform

Medicilon has been conducting comprehensive preclinical research for ophthalmic drugs since 2013, with extensive experience from active pharmaceutical ingredients and formulations to pharmacodynamics, pharmacokinetics, and safety assessments, and has contributed to the approval of multiple ophthalmic drugs.

Medicilon preclinical ophthalmology research platform integrates advanced drug administration technologies and analytical methods, high-quality equipment, and a team of experienced R&D professionals. It provides customers with ophthalmic drug development needs with high-quality and efficient experimental research services, as well as professional support for registration applications and project management services.

Medicilon preclinical ophthalmology research platform has completed multiple projects on the safety studies of ophthalmic formulations, including eye drops; and has conducted several projects on pharmacodynamic and pharmacokinetic studies for intravitreal injections, subretinal injections, and eye drops. It has also completed full sets of preclinical research projects for new drugs such as ophthalmic solutions or intravitreal injections. Currently, we are conducting several projects for the pharmacodynamic, pharmacokinetic, and safety assessment of ophthalmic solutions and intravitreal injections.

## Service Scope & Capabilities

### Pharmacodynamics

- Dry eye
- CNV
- Dry AMD
- .....

### Pharmacokinetics

- Single/multiple dose PK
- ADME
- .....

### Toxicology

- Single/multiple dose toxicity test
- Immunogenicity test
- .....

### CMC

- Chemical synthesis
- Formulation
- Production and quality systems

## Comprehensive Instrument Detection System

The key and difficulty in the research and preclinical evaluation of ophthalmic drugs lie in using the right instruments and equipment for delicate operations and examinations of the eyes in experimental animals. The Medicilon ophthalmology research team, leveraging years of rich practical experience and advanced equipment, solves various complex issues in ophthalmic research for clients. Focusing on details and quality control, they provide clients with stable and high-quality research services. SPECTRALIS® HRA + OCT is an ophthalmic imaging system with the latest upgradable modular design. Utilizing this system, we can assist our clients in conducting examinations such as fundus fluorescence angiography and optical coherence tomography on experimental animals.

### The detection items include the following contents:

- Infrared fundus imaging (IR)
- Red-free fundus imaging (RF)
- .....
- Fundus fluorescence angiography (FFA)
- Optical coherence tomography (OCT)



Heidelberg Ophthalmic Laser Diagnosis Device  
(Spectralis HRA + OCT, Germany)



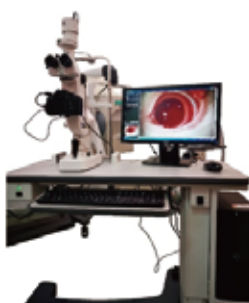
ROLAD Electrophysiological Diagnostic Systems  
(RETI-port/scan 21, Germany)



Digital fundus angiography device  
(Model: APS-BER)



Fundus color imager  
(Clear View 2, Japan)



Slit lamp microscope  
(Model: YZ5T)



Fundus Laser Device  
(Vitra, France)



**Tonometer**  
(Icare Tono, Finland)



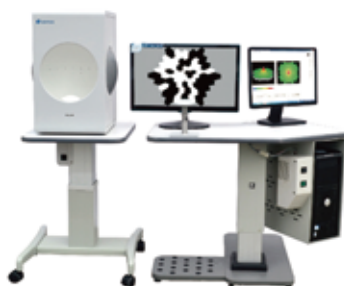**Indirect Ophthalmoscopy**  
(Model: YZ25C)



**Ophthalmology microscope**  
(Model: M220, Leica)



**Optical Coherence Tomography**  
(model: VG100D, China)



**ROLAD Electrophysiological Diagnostic**  
(Spectralis HRA + OCT, Germany)



**MicroClear Ophthalmoscopy**  
(Model: CRO PLUS, China)

## Species of Ophthalmic Animals

### Rodent:

- Mouse
- Rat
- Guinea pig

### Non-rodent species:

- Monkey
- Rabbit
- Dog
- Minipig

## Animal Models for Ocular Diseases

- Diabetic retinopathy (DR)
- Choroidal neovascularization (CNV)
- Retinal neovascularization (RNV)
- Dry age-related macular degeneration (AMD)
- .....
- Corneal neovascularization
- Corneal alkali burn
- Allergic conjunctivitis
- Dry eye syndrome

# Pharmacodynamics Studies

## Choroidal Neovascularization Model

Laser-induced CNV model is a classical model for wet Age-Related Macular Degeneration (AMD). CNV is a typical pathological feature of wet AMD.

### Detection Indicators:

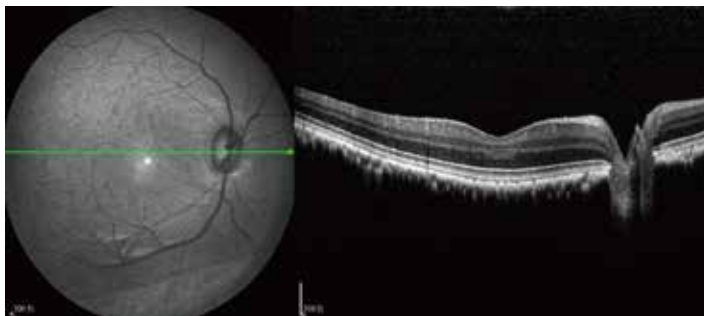
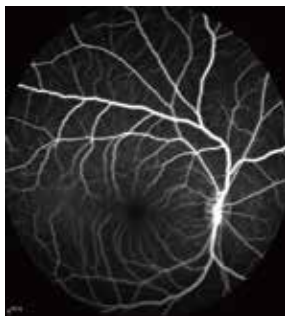- General ophthalmic examination
- Fundus photography
- FFA/OCT
- Ocular tissue pathology

### Main Pharmacodynamic Indicators:

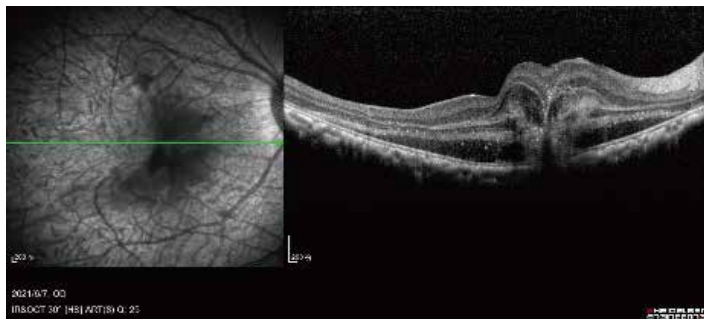
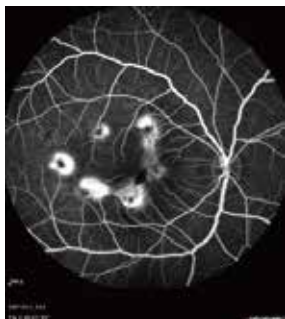- FFA - Determine the extent of CNV by the fluorescence leakage of the lesions, measure the area of fluorescence leakage of the IV-grade lesions.
- OCT measures the height of the high-reflectivity band beneath the retina (in the area of the 4-grade lesions).

### Note:

- Considerations for the setting of administration times and detection frequencies for different types of drugs.



Four weeks after laser.





## Glaucoma Model

### Model Success Criteria:

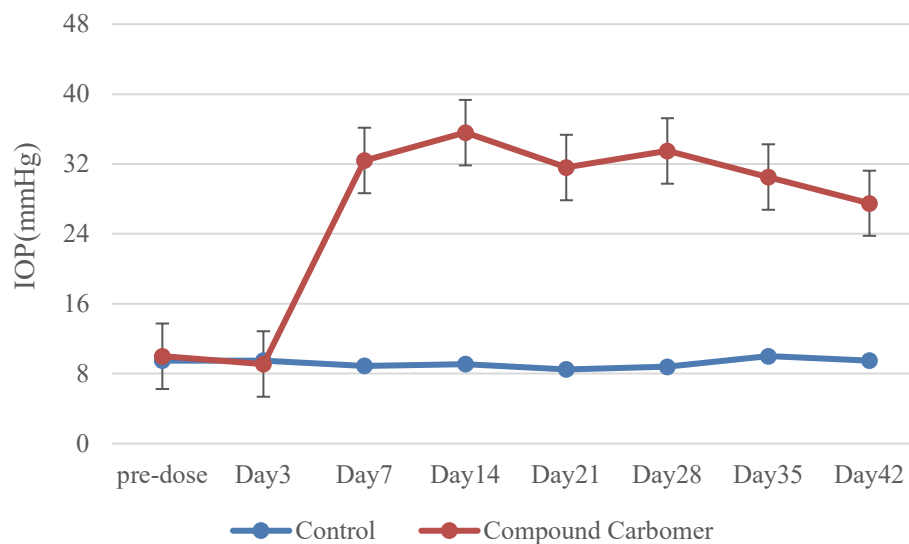
- IOP > 20 mm Hg, and the duration is > 1 week, indicating successful induction of glaucoma.

### Main Mechanism:

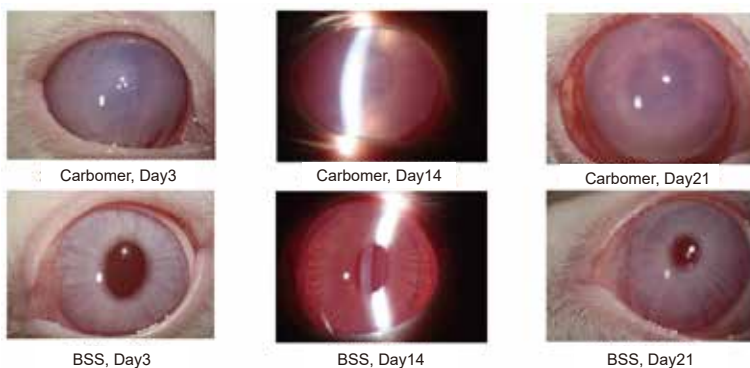
- The carbomer solution is most viscous at a pH of 6 to 12, and after being injected into the anterior chamber, it turns into a gel-like substance that blocks the outflow of aqueous humor as the pH increases.

### Detection Indicators:

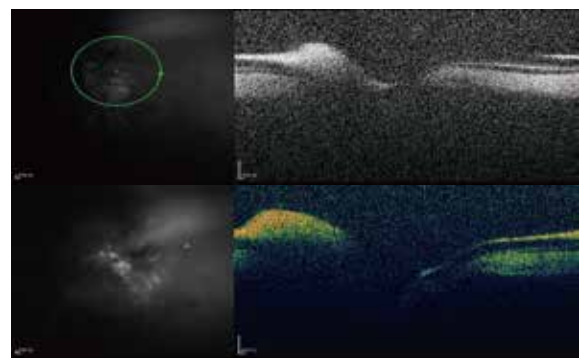
- General ophthalmic examination
- Fundus photography
- Optic disc and RNFL thickness
- FFA/OCT
- IOP
- Ocular tissue pathology



Intraocular pressure change



Process of ocular surface tissue change



Fundus change

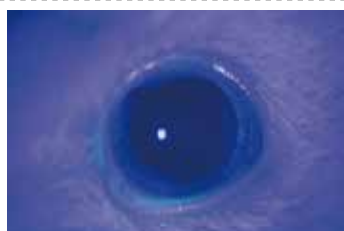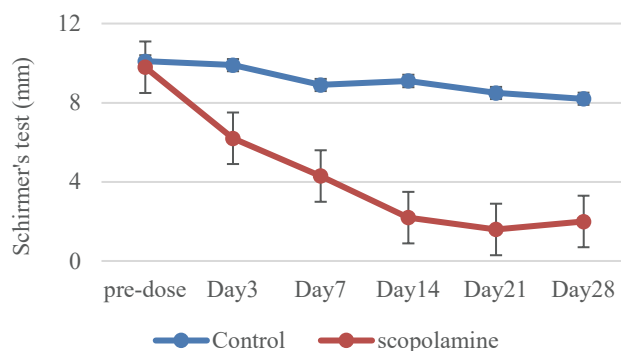
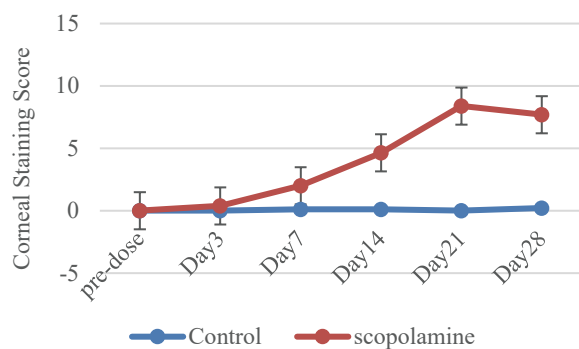
## Dry Eye Model

### Modeling Method:

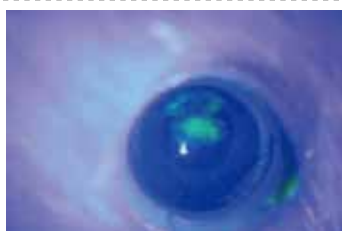- Healthy rats are selected and administered scopolamine via subcutaneous injection four times daily for 4 weeks, and placed in a dry room. Schirmer's test and corneal conjunctival fluorescein staining are performed 1, 3, 5, 7, 14, and 28 days before and after the start of administration. At the end of the administration, the conjunctiva, cornea, and lacrimal gland tissues are taken for optical microscopic examination.

### Detection Indicators:

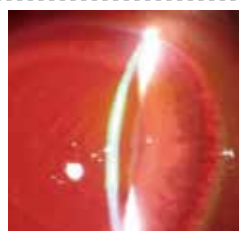
- Tear film break-up time (BUT)
- Ocular tissue damage scoring
- Tear fluid
- Tissue pathology



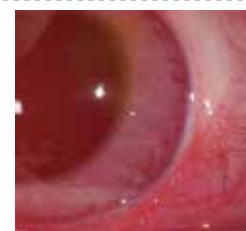Control



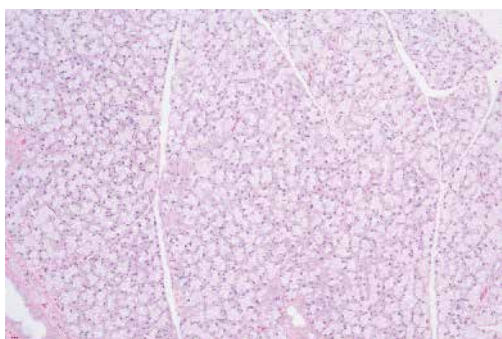
Scopolamine



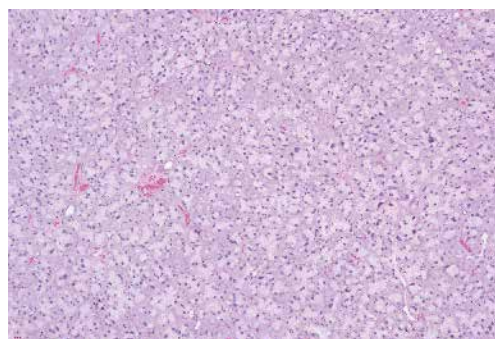
Corneal  
neovascularization



Conjunctival  
vasodilation



Control, Lacrimal Gland, Normal (100x)



Scopolamine, Lacrimal Gland, Normal (100x)

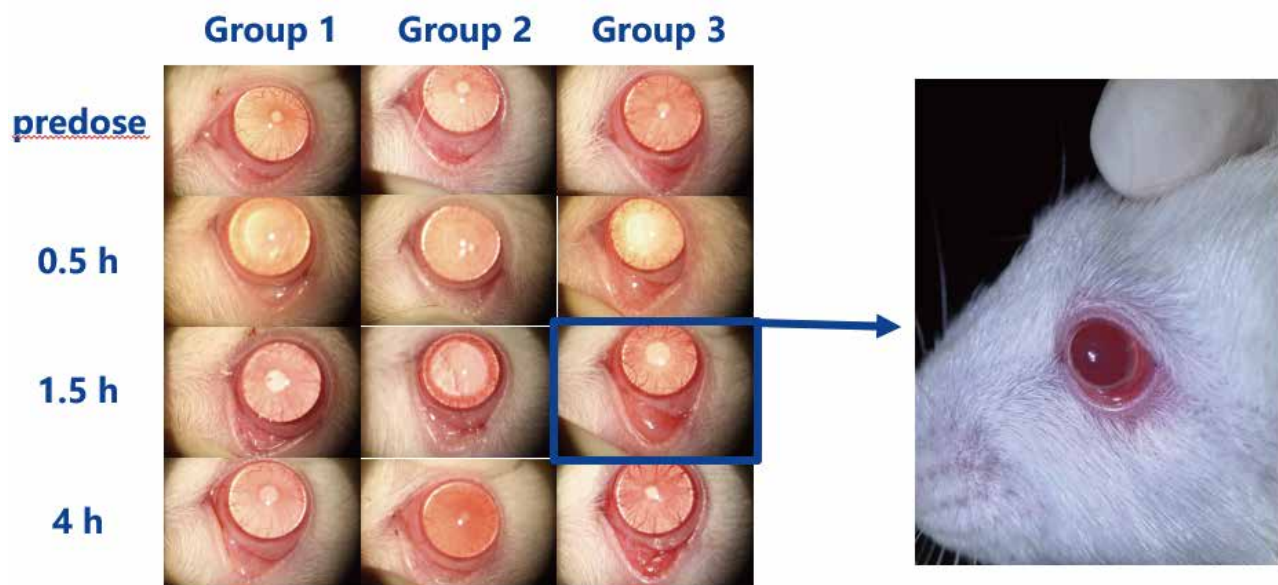
## Allergic Conjunctivitis (AC) Model

### Modeling Method:

- Intraperitoneal injection of ovalbumin (OVA) induced specific immune response and sensitized the body systemically. Later, topical eye drops of OVA were used again to induce allergic conjunctivitis.

### Detection Indicators:

- Ocular surface observation
- Serum IgE
- Eye irritation score
- Tissue pathology

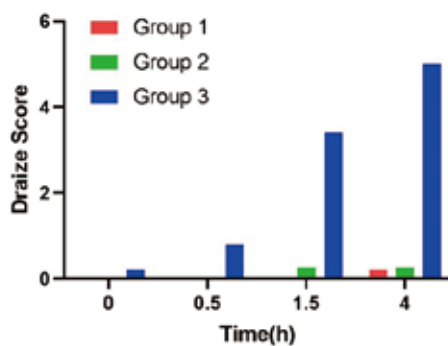


Group 1: 0.9% NaCl (ip)+ 0.9% NaCl (eye drop)

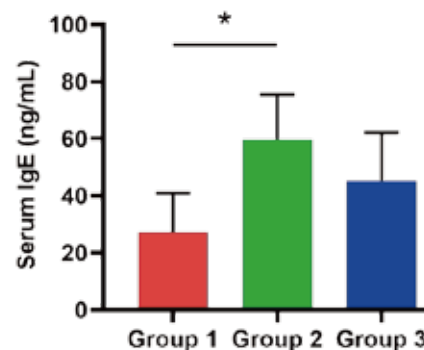
Group 2: OVA (ip)+ 0.9% NaCl (eye drop)

Group 3: OVA (ip)+ OVA (eye drop)

Ocular surface Observation



Eye Irritation Score



Serum IgE



## Retinal Neovascularization (RNV) Model

### Modeling Method:

- Induction of retinal neovascularization by intravitreal injection of DL-2-aminoadipic acid (DL-AAA)

### Detection Indicators:

- General ophthalmic examination
- Fundus photography
- FFA/OCT
- Ocular tissue pathology

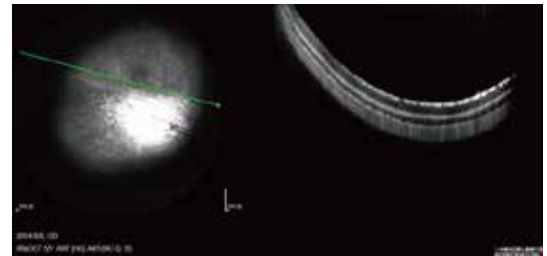
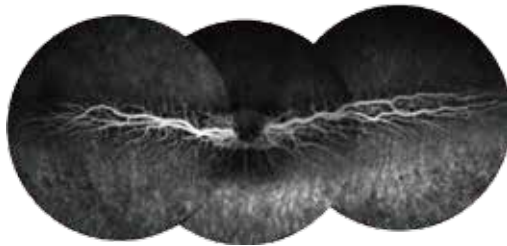### Results:

- FFA results: showed significant fluorescence leakage from the fundus in DL-AAA model group
- OCT results: Degeneration, detachment, and retinal thinning in aflibercept efficacy & DL-AAA model group

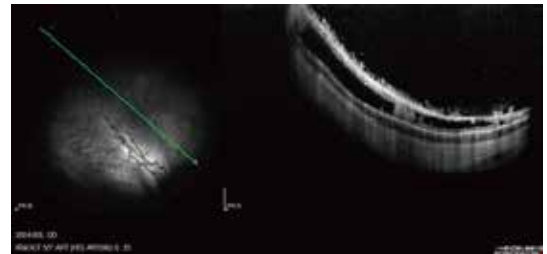
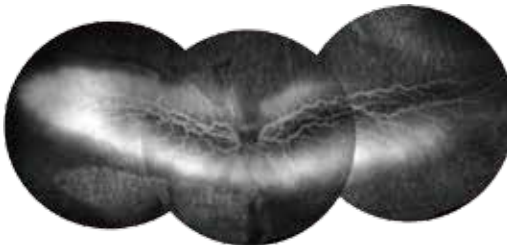FFA

OCT

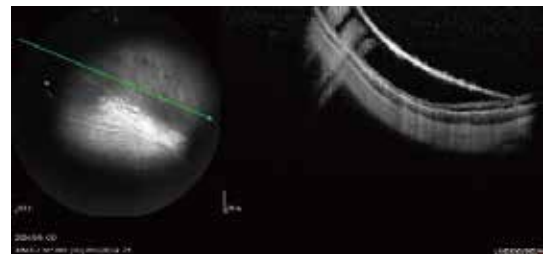

0.9% Saline



DL-AAA



Aflibercept+DL-AAA





## Alkali Burn of Cornea Model

### Modeling Method:

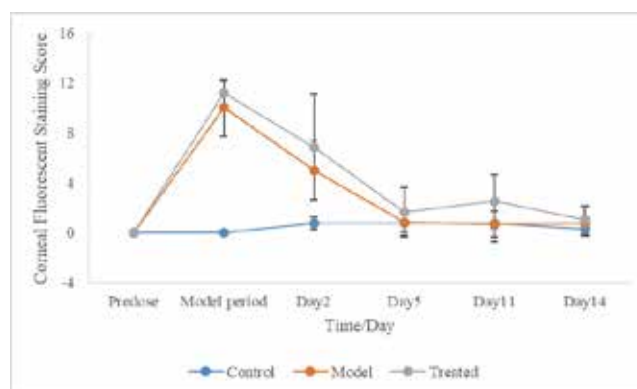
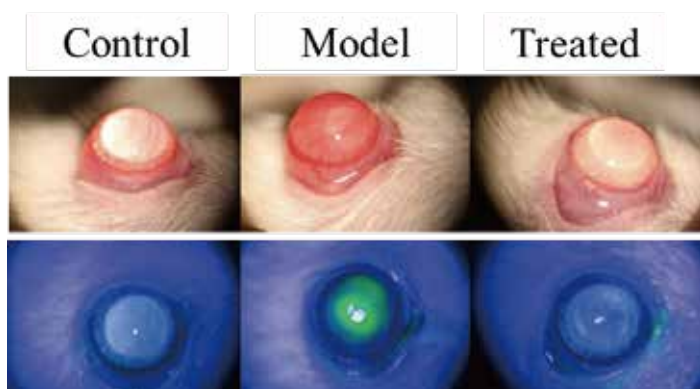
- Filter paper dipped in 1M sodium hydroxide solution placed in the center of the rat cornea.

### Detection Indicators:

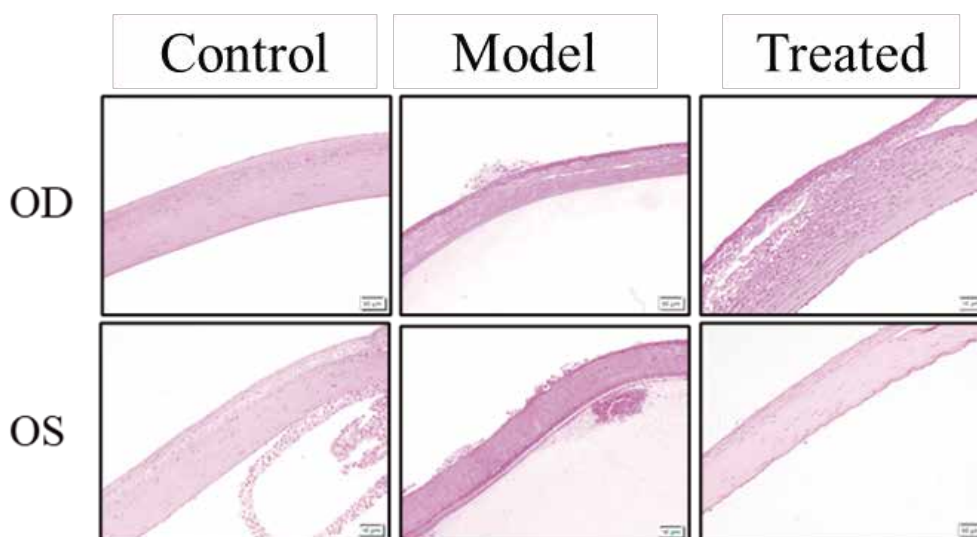
- Slit-lamp examination
- Corneal fluorescein staining
- Histopathology

### Results:

- Edema, fluorescein sodium staining was obvious, and inflammatory exudation occurred in the corneal epithelium; The corneal injury was gradually repaired in treated group.



Corneal fluorescein staining



Corneal tissue HE staining



## Dry AMD Model

### Modeling Method:

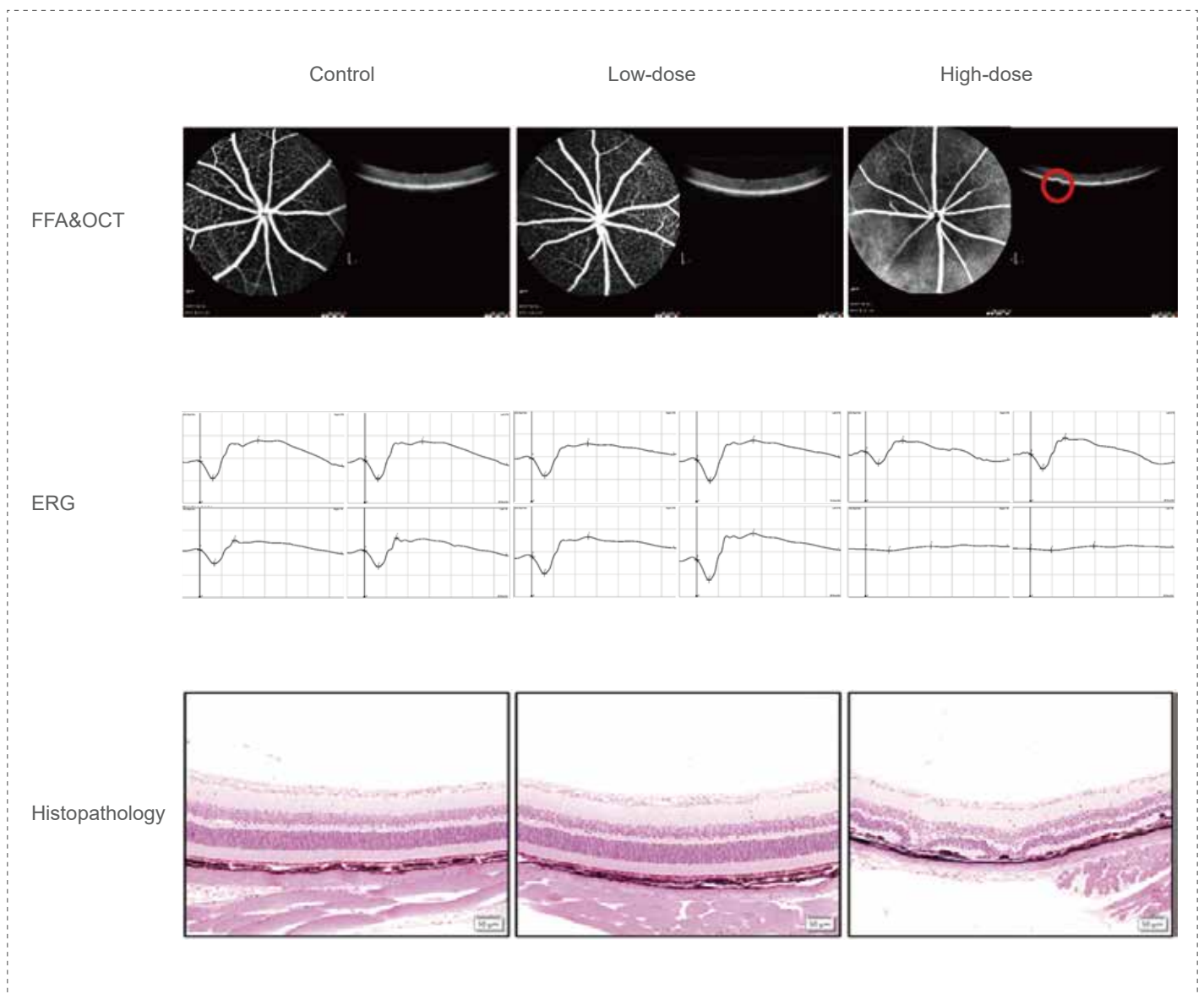
- Single intraperitoneal injection of sodium iodate solution.

### Detection Indicators:

- Ophthalmic examination
- ERG examination
- OCT and FFA examination
- Histopathology

### Results:

- Retinal thickness became thinner, drusen form, geographic atrophy, and retinal pigment epithelial layer, outer nuclear layer, and outer plexiform layer atrophy; ERG a and b waves extinguish.



# Pharmacokinetic Studies



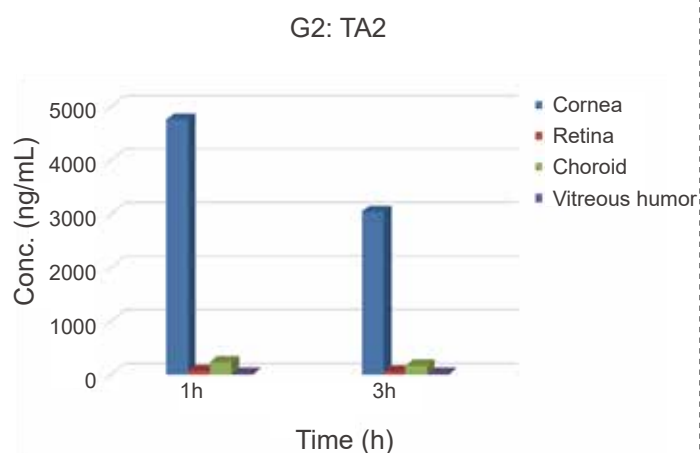
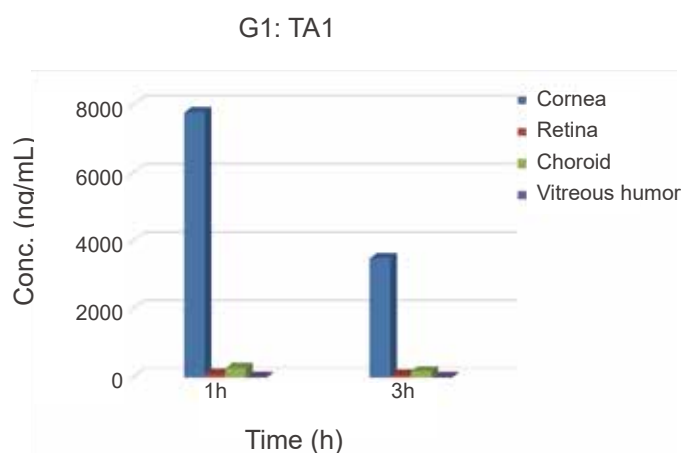
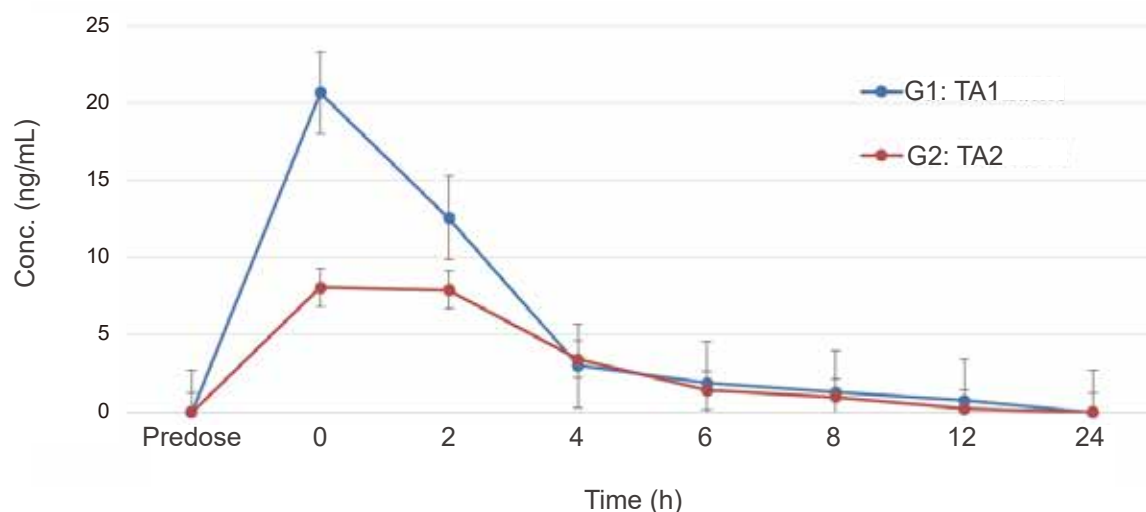
## Eye Drops in Dutch Rabbits - Small Molecule (Suspension)

### Methods:

- Blood samples were collected at different time points to detect the concentration of test article and calculate the relevant parameters to investigate the PK characteristics *in vivo*. Eye tissues were collected at 1h and 3h, and the drug concentration at different time was calculated.

### Conclusion:

- For ocular surface administration, systemic exposure is low; The drug concentration in the cornea is relatively high (the drug is distributed more in the anterior segment of the eye and less in the posterior segment of the eye, which is consistent with the PK characteristics of conventional eye drops)





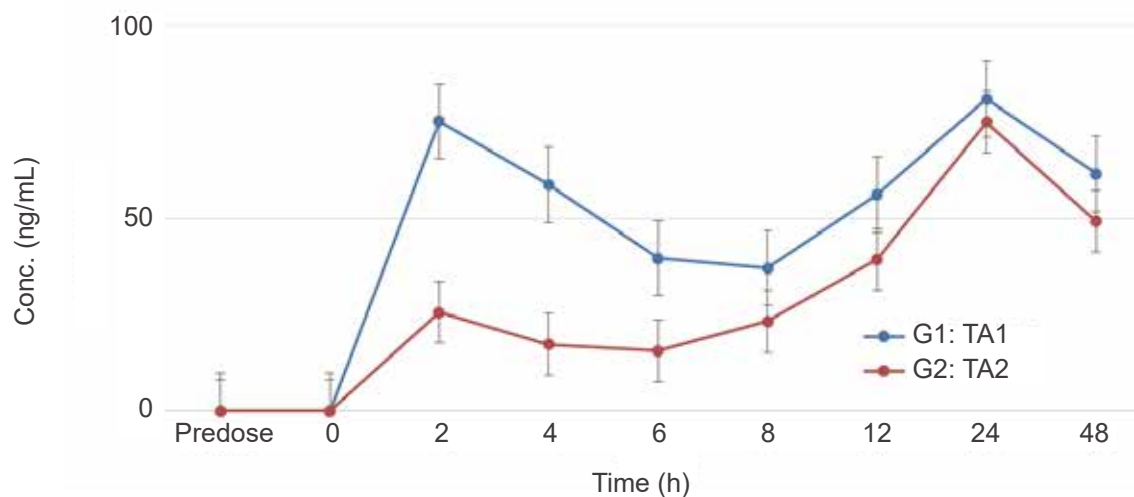
## Intravitreal Administration in Dutch Rabbits - Monoclonal Antibodies (mAbs)

### Methods:

- Blood samples were collected at different time points to detect the concentration of test article and calculate the relevant parameters to investigate the PK characteristics *in vivo*.

### Conclusion:

- After intravitreal administration, the drug concentration in the serum is not high, the drug lasts for a long time, with a long half-life.



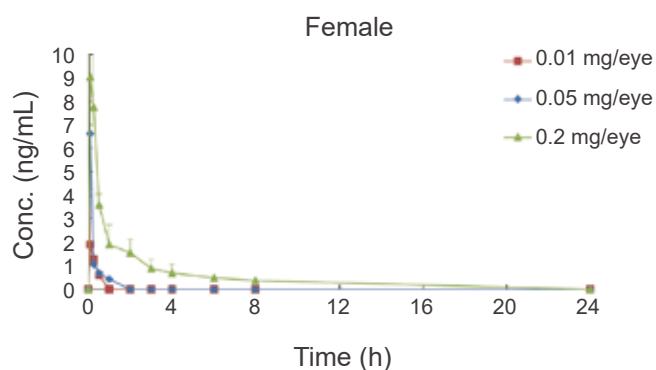
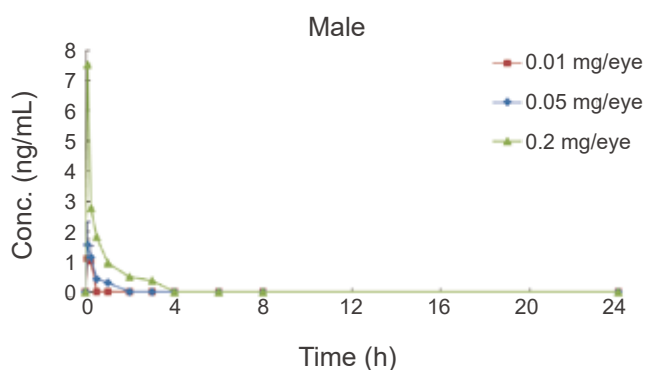
## Eye Drops in Beagle Dogs - Small Molecule (Solution)

### Methods:

- Blood samples were collected at different time points to detect the concentration of test article and calculate the relevant parameters to investigate the PK characteristics *in vivo*.

### Conclusion:

- After eye drops administration, plasma drug exposure is low, with a short half-life. No difference between male and female animals





# Toxicology Studies


## Toxicology Services (GLP & Non-GLP)

- Single/multiple dose toxicity
  - Reproductive toxicity
  - Genotoxicity
  - Toxicokinetic
- Safety pharmacology
  - Immunogenicity
  - Local toxicity
  - Carcinogenicity

## Eye Drops in New Zealand Rabbits

**Experimental design:**

- Experimental design: Chemical drug
- New Zealand rabbits: Eye drops once a day for 28 days
- Indications: Myopia



**Routine detection indicators:**

- Body weight, food consumption, body temperature, clinical examination, etc.

**Special ophthalmic detection indicators:**

- Intraocular Pressure (IOP), ocular irritation scoring, Optical Coherence Tomography (OCT) and Fundus Fluorescein Angiography (FFA), Electroretinography (ERG), tissue pathology, etc.

**Result:**

- No abnormal clinical symptom was observed

Group	Animal numbers		Test article	Dose level (mg/eye)	Dose concentration (mg/mL)	Dose volumn (µL/eye)	Dose frequency
	M	F					
1	3 <sup>+</sup> +2 <sup>#</sup> +2 <sup>&amp;</sup>	3 <sup>+</sup> +2 <sup>#</sup> +2 <sup>&amp;</sup>	Saline	0	0	50	Once daily for 28 consecutive days
2	3 <sup>+</sup> +2 <sup>#</sup> +2 <sup>&amp;</sup>	3 <sup>+</sup> +2 <sup>#</sup> +2 <sup>&amp;</sup>	XX001	0.005	0.1	50	
3	3 <sup>+</sup> +2 <sup>#</sup> +2 <sup>&amp;</sup>	3 <sup>+</sup> +2 <sup>#</sup> +2 <sup>&amp;</sup>	XX001	0.05	1	50	
4	3 <sup>+</sup> +2 <sup>#</sup> +2 <sup>&amp;</sup>	3 <sup>+</sup> +2 <sup>#</sup> +2 <sup>&amp;</sup>	XX001	0.250	5	50	

## Intravitreal Injection in Rhesus Monkeys

### Experimental design:

- Experimental design: Monoclonal antibody
- Rhesus monkeys: Administered once every 2 weeks, for a total of 14 times
- Indications: Wet-AMD



### Routine detection indicators:

- Body weight, food consumption, body temperature, clinical examination, ADA etc.

### Special ophthalmic detection indicators:

- Intraocular Pressure (IOP), ocular irritation scoring, Optical Coherence Tomography (OCT) and Fundus Fluorescein Angiography (FFA), Electroretinography (ERG), tissue pathology, etc.

### Result:

- No abnormal clinical symptom was observed

Group	Animal numbers		Test article	Dose level (mg/eye)	Dose concentration (mg/mL)	Dose volumn (μL/eye)	Dose frequency
	M	F					
1	3#+2 <sup>±</sup>	3#+2 <sup>±</sup>	Saline	0	0.0	50	Administered once every 2 weeks for a total of 14 administrations, followed by a 4-week recovery period
2	3#+2 <sup>±</sup>	3#+2 <sup>±</sup>	XXX	1.25	25	50	
3	3#+2 <sup>±</sup>	3#+2 <sup>±</sup>	XXX	2.5	50	50	
4	3#+2 <sup>±</sup>	3#+2 <sup>±</sup>	XXX	4.0	80	50	



### MEDICILON

Email: [marketing@medicilon.com](mailto:marketing@medicilon.com) Website: [www.medicilon.com](http://www.medicilon.com) Tel: +1 (617) 888-9294

USA: 20 Maguire Road, Suite 103, Lexington, MA 02421

China: 585 Chuanda Road, Pudong, Shanghai, 201299